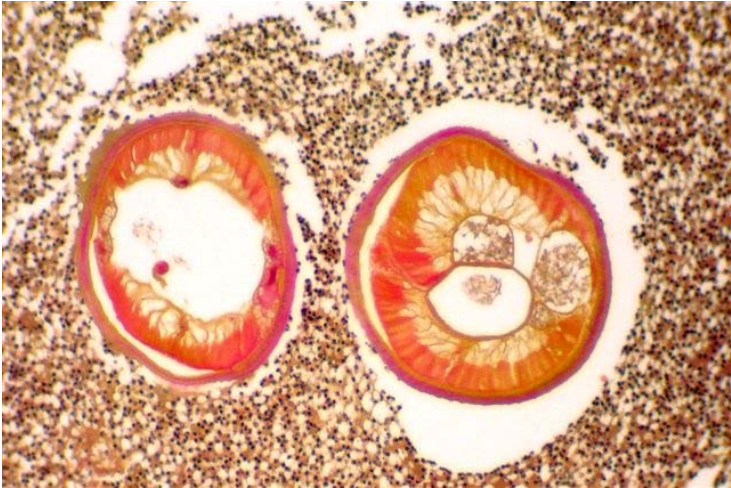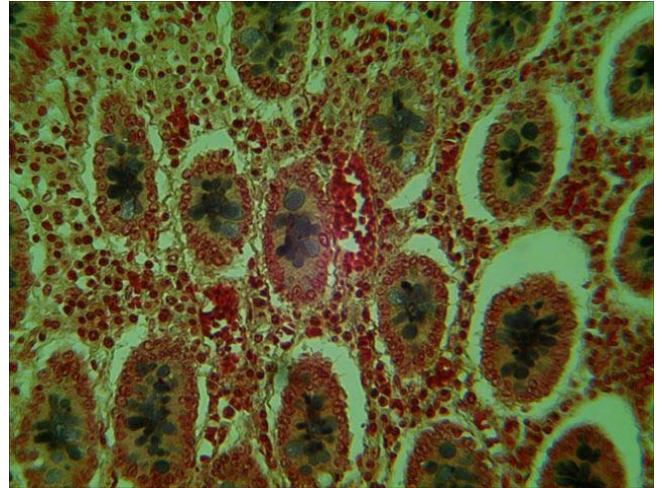
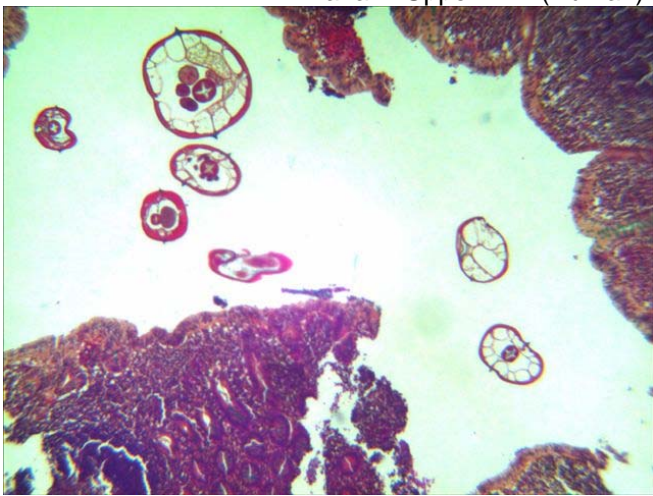


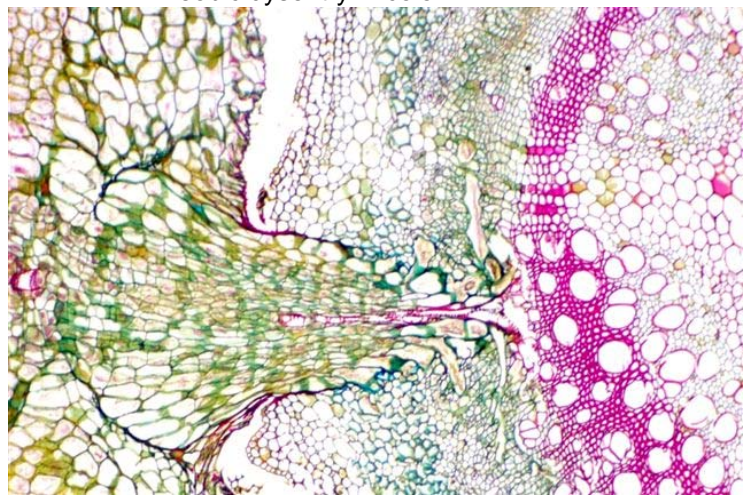
Filaria in Upper Arm (Human)



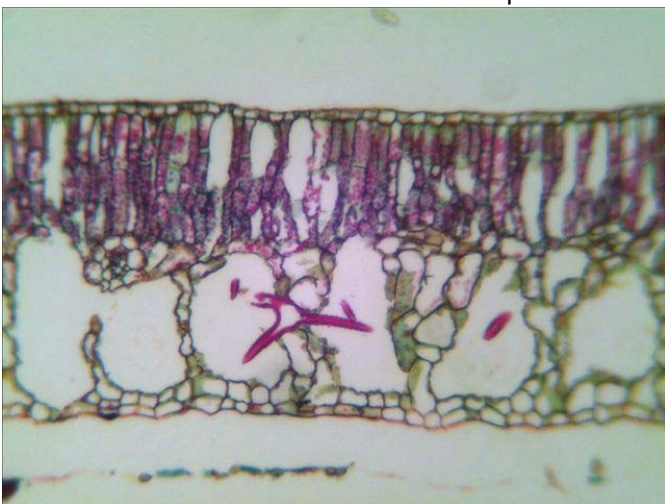
Ameobic dysentery in colon



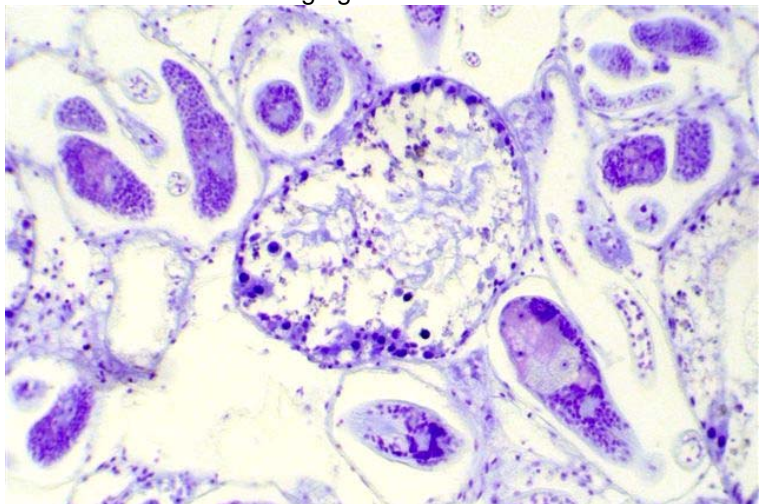
Pin worms in apendix



Dodder on Stinging Nettle



Water lily aestival scleroid



Bilhazia Sporocysts